

The Dent-Liner™

A Bulletin Dealing With Issues For Dental Health Professionals

Prosthetic Recovery Utilising the Friction Splint FS1



Peter T. Pontsa, RDT has over 40 years of experience in the dental profession. In 1991 he established Dent-Line of Canada Inc. and is currently president of this dental supply company. He is a leader in superior professional techniques in fixed and removable restorations and he shares this knowledge through articles and seminars which he regularly provides. Peter is a past president of the College of Dental Technologists of Ontario. He is also pleased to be involved as co-publisher of Spectrum Denturism.

Special Interest Articles:

- Prosthetic Recovery Utilising the Friction Splint FS1 1
 - A Definitive Diagnostic Wax-Up Technique 2
- ### Individual Highlights:
- Bredent's new Quick Change Instruments 2
 - Bredent's Transfuser Investment Tool 2
 - Trade News 4
 - Announcements 4

As a result of a comprehensive treatment plan, patients who receive a removable prosthesis will benefit from the Friction Splint FS1 screw system. The system is suitable for all ceramic crowns, conventional crown and bridge work overimplants and bar restorations. FS1 consists of a titanium screw and plastic sleeve. It works and functions much like an expansion screw and creates a stress free restoration because any potential stress is absorbed by the plastic sleeve. With the friction splint system there are advantages to having the opportunity to be able to recover the restoration for examination when circumstances are indicated to do so or on a recall visit. Numerous restorations today are cemented on implants for the life time of the restoration, so when a patient fractures their porcelain or an abutment screw becomes loose under the cemented restoration there is little chance of recovery. Patients are shocked to find that it can't be repaired and that they require a total replacement restoration. The removal of the restoration is paramount so that the screw and the implant or the soft tissue surrounding the implant site can be examined. We also know from past experience that with deep crown margins in the peri-implant sulcus, that it is very difficult to remove excess cement, which may lead to inflammation of the soft tissue. In cases like this the margin should be located 1.0 mm to 1.5 mm subgingivally. The analysis of clinical trials shows the existence of several factors essential to the long term success of

any implant prosthesis; they are aesthetics, recovery, and passivity of the framework, occlusion, and ease of fabrication, retention and cost. Clinicians who restore enough implants over time will find that abutment screws will loosen and break, porcelain will fracture, solder and solid joints will break and implants will fail. Fabricating frameworks that are static and are screw retained is complex due to the extent of discrepancies that are built in by conventional manufacturing techniques. Nevertheless CAD/CAM milling in titanium is improving the passive fit of implant bars. In many instances when screws become unfastened it may not be due to the design of the implant, but may be very likely be caused by bruxism, stress overload and controllable causes. Because of the lack of proprioception on the part of the patient, they tend to put elevated occlusal forces on implants. The outcome of this is amplified stress overload conditions that go unnoticed. Even with the advent of the 2nd generation implants which address these issues, it does not surpass the other reasons to remove or recover the restoration from the implant for examination. This is important when the clinician has chosen to re-examine the soft tissue around the implants for irritation or inflammation. Other rational may be to adjust or make changes in pontic or ridge adaptation to repair broken or chipped porcelain or to add proximal contacts which can open up over time.

continued on page 2

A Definitive Diagnostic Waxing Technique

The use of diagnostic wax ups as a treatment modality has become increasingly important in the pre-treatment stages of dental restorations. The process helps eliminate most of the unforeseen negative outcomes. The visual concept of this technique increases patient acceptance and satisfaction. It virtually allows the patient to see their new look and smile prior to fabrication in the laboratory. In the final analysis, patients and dental professionals must exchange ideas and conceptions clearly

and concisely to create successful aesthetics. These wax ups are a vital communication tool for predictable results which allows careful evaluation of anterior guidance, cuspid rise and functionality. A vast majority of the population desire a brighter, cleaner and more attractive smile because of media focus through various "extreme make over" television programs. Typically they are trying to correct chipped, unevenly spaced, stained, discoloured or

continued on page 2

Prosthetic Recovery Utilising the Friction Splint cont'd...



The Friction Splint FS1 Pin & Sleeve



Using the modelling pins



The subframe and secondary wax-ups are ready for the ceramic spacers.



Bredent's NEW Quick Change System.



Bredent's NEW Transfuser Investment Tool

Another problem that can be solved by cross-pinning with the friction splint FS1 is the occlusal access holes that are in the aesthetic zone. These openings are unattractive and spoil the occlusal surface and produce weak points in the porcelain to metal interface. To avoid using these occlusal access points the friction splint screw and tube can be utilized to connect the implant prosthesis to the implant abutments, implants or bars. Cross-pinning with a screw system diagonally into the restoration and implant, allows prosthetic recovery without detriment to the implant or abutment alignment. The friction splint is intended for this type of function where recovery without the use of occlusal access points is favoured. The friction fit system has superior stability because of the bilateral support created in the implant abutment and implant supported bar. Another advantage to the FS1 is the rescue of crowns with defective screw connections, by retooling the damaged lingual screw hole to accommodate the FS1 the case can be saved from being remade. During recalls the plastic tube can be easily removed and replaced as seen fit by the clinician. There are many predicaments involving cemented implant restorations, that is why recovery is foremost when commencing a treatment plan. The FS1 is indicated for diagonal cross-pinning restorations to implants and bars when repairs,

modifications or the evaluation of soft tissue is necessary. **Source: Peter T. Pontsa**

References;

- (1) Chee W., Jivraj S., Screw versus cemented implant supported restorations, *British Dental Journal* 2006; 201:501-507.
- (2) Misch C.E., Screw-retained versus cement-retained implant supported prosthesis, *Practical Periodontics of Aesthetic Dentistry* 1995; 7:15-18.
- (3) Chee W., Felton D.A., Johnson P.F., Sullivan D.Y., Cemented versus screw-retained implant prosthesis: which is better?, *International Journal of Oral Maxiofacial Implants* 1999;14 137-141.
- (4) Cho S.C., Small P.N, Elain N., Tarnow D., Screw loosening for standard and wide diameter implants in partially edentulous cases; Three to seven year longitudinal data. *Implant Dentistry*; 2004; 13: 245-250.
- (5) Guichet D.L., Caputo A.A.,Choi H., Sorenson J.A., Passivity of fit and marginal opening in screw or cement-retained implant fixed partial denture designs, *International Journal of Oral Maxillofacial Implants* 2000; 15: 239-246.
- (6) Hebel K.S.,Gajjar R.C., Cement retained versus screw-retained implant restorations: achieving optimal occlusion and aesthetics in implant dentistry, *Journal of Prosthetic Dentistry* 1997;77:28-35.
- (7) Michalakos K.X., Hirayama H., Garefis P.D. Cement-retained versus screw-retained implant restorations: a critical review. *Int. Journal Oral Maxillofacial Implants* 2003; 18: 719-728

Featured Product: Bredent's NEW Quick Change System

It is not uncommon to find a technician's lab area overloaded with the different kinds of instruments he needs for his ceramics, wax models and prosthetic work. Because of this, well structured, clearly arranged and proper storage is next to impossible. In the past, when instruments were frequently exchanged via the use of a thread connection, some models even required a key to be used to position the inserts inside the handle; this made it difficult to change instruments easily. Quick Change has been developed to put and end to these

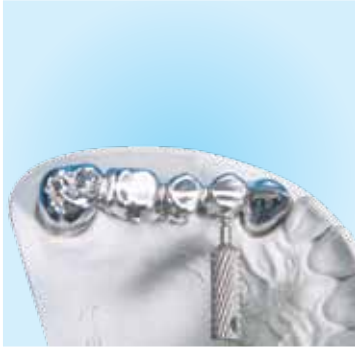kinds of problems. **Quick Change** is a system consisting of a handle with integrated magnets and high-precision retaining sockets. This combination allows one to take up and release the various inserts very quickly. The blade holder is suitable for 12 inserts (brushes, special instruments, standard blades and adapter). Even the popular "Greenstein" ceramic spatula tip can be integrated into the Quick Change system with an especially developed thread adapter. **For your free brochure or additional information contact us at 1-800-250-5111!**

Featured Product: Bredent's Transfuser Investment Tool

When investing a wax-up or an impression, quite frequently air gets entrapped - especially in narrow and inverse areas - which may cause undesired bubble formation. So far the solution has been to use instruments and brushes for the preparation. Unfortunately, sharp-edged instruments bear the risk of damaging both the delicate wax-up and impression. When using brushes, it is possible to transfer excess fluids, and if the brush is rather dry it may withdraw

some moisture. Both traditional methods may affect the expansion behaviour of investment compounds. The curved and flexible silicone tip of the Transfuser allows a gentle, damage and bubble-free application prior to standard filling procedures. The smooth and dense surface provides excellent gliding characteristics for gypsums and investment compounds, thus ensuring the material will be bubble-free. **For details call us today at 1-800-250-5111!**

Prosthetic Recovery Utilising the Friction Splint cont'd...



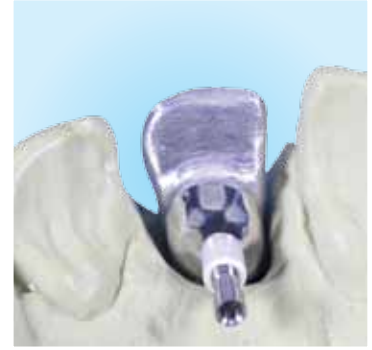The universal screw driver facilitates removal and insertion.



The screw is turned half way into the sleeve and positioned using tweezers.



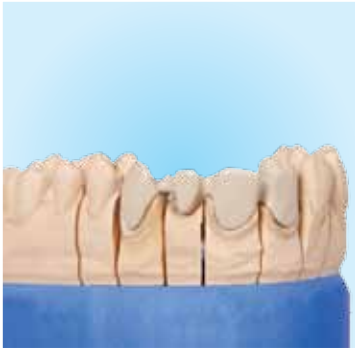The FS1 screw and tube are placed to hold the primary unit to the substructure.



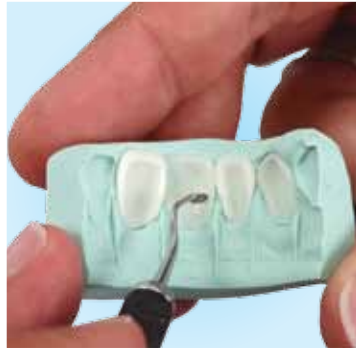
The damaged threads can be retooled for FS1.

A Definitive Diagnostic Waxing Technique

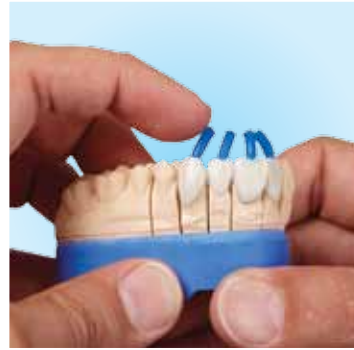cont'd...



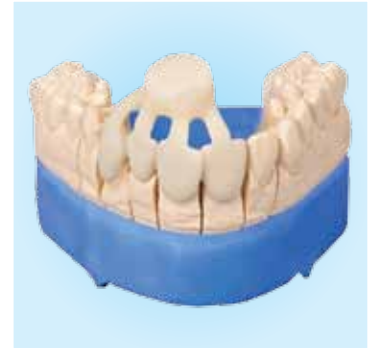The framework is opaqued in the usual manner.



The pre-selected wax facings are fitted to the matrix index.



A 3.0 mm sprue no more than 8 mm. long is used.

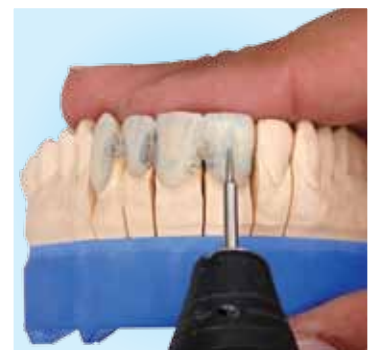

The pressed framework is ready for cutting of the porcelain sprues.

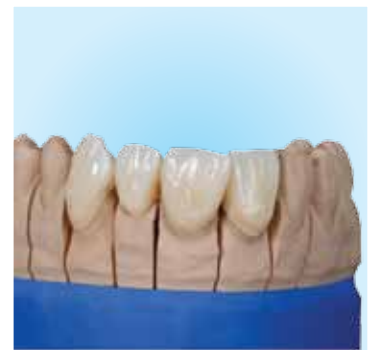or even slightly crooked front teeth. Usually veneers or laminates can provide these individuals with a completely new looking smile with just a few adjustments. Most often the pre-operative model is prepared and ivory wax is used to achieve the desired aesthetics. This process is time consuming and requires an experienced technologist to be able to create anything meaningful. Fortunately these issues have been addressed in a new product produced by Renfert called GEO Aesthetics Wax Veneers. These veneers can be utilized for diagnostic wax ups, temporaries, pressable ceramics or porcelain veneers. With these anatomically preformed wax patterns one can realise up to 70% savings in time as opposed to waxing up traditionally. In addition to the labour savings, technologists and laboratories can benefit from the consistency of each case produced from this system. The GEO waxes used are of high quality and 100% ash free. An anterior assortment kit includes six upper anterior models and two lower anterior models. These are used as a guide for arrangement and shape of the diagnostic wax up. After a mould has been selected using one of the models,

the appropriate veneers can be selected from the corresponding tray in the kit. The same applies for the lower. The kit includes the GEO sculpting waxes which are made up of the same high quality materials that leave no ash or residue. The "golden mean" was a design factor in the development of this wax veneer system. Patients who have peg shaped maxillary laterals, diastemas, short clinical crowns, excessive gingival display and orthodontic mal-occlusion can be helped with a orthodontic, periodontic and prosthodontic approach. Porcelain laminate veneers or crowns and bridges can be delivered after a diagnostic wax up using pressable ceramics. Diagnostic visualization of interdental spacing can be overcome with duplicated models sectioned stone teeth, full contour diagnostic wax ups and occlusal putty impressions. Another area the GEO Aesthetics veneer technique can be utilised is in the fabrication of a screw retained implant supported wax pattern that enables the restorative team to predict the final outcome of the completed prosthesis.

continued on page 4



Corrections and character grinding.



The finished product.

dent-line of canada

1170 Concession 4,
Adjala, R.R. # 1
Loretto, Ontario,
LOG 1L0

PHONE:
1-800-250-5111
Or
519-942-9315

FAX:
519-942-8150

EMAIL:
Info@dent-line.com

We're on the Web!
See us at:
www.dent-line.com

About Our Organization...

The Dent-Liner; Vol. 13 No. 2
Publisher; Peter T. Pontsa RDT
Editor; A. van Breemen, BA

Subscription Rates:
Canada 1 Year \$ 6.00
USA 1 Year \$ 8.00
International 1 Year \$16.00

Continuing education
credits apply for a review of
this newsletter. For details
contact the Quality Assurance
committee in your jurisdiction.

Receipt of the dent-liner implies consent
under the P.I.E.D.A. unless you advise dent-
line of canada either orally or in writing
that you wish not to receive this newsletter.

A Definitive Diagnostic Waxing Technique

cont'd...

Aesthetics and function are equal concerns when restoring the anterior dentition. New ideas in restorative dentistry have developed better solutions through bonded porcelain veneers and pressables, which while looking good also support occlusal forces and masticatory function. The final treatment outcome greatly depends on the therapeutic approach that is approved whereby limiting dentin exposure and preserving enamel. The GEO Aesthetics wax up technique provides a significant amount of diagnostic information and a visual aid in removal of tooth substrate from the preparation. The significance of the diagnostic wax up technique is vital to the completion, functionality and the durability of the restoration. The wax up can be a template for the final restoration because it is a 100% ash free wax, which is ideal for the pressable ceramics technique. Provisional restorations are quick and easy to fabricate since the mould and shape have already been created. By using a silicone putty matrix as a visual aid, adequate tooth preparation

is achieved. The GEO Aesthetics technique is a powerful tool for communicating with patients, since they can see a three dimensional representation of their final restoration.

Source; Peter T Pontsa, RDT

References:

- (1) L. Claman, M.A. Alfaro, A. Mercado, "An Interdisciplinary Approach for Improved Esthetics Results in the Anterior Maxilla", *Journal of Prosthetic Dentistry*, Vol. 89 Issue 1, page 1-5, January 2003.
- (2) N. Charmattayompol, S.X. Wong, "Diagnostic Management of Interdental Spacing", *Journal of Prosthetic Dentistry* Vol. 84, Issue 4, Page 467-469, October 2000.
- (3) P. Proussaefs, "A Maxillary Screw Retained Implant Supported Diagnostic Wax Pattern", *Journal of Prosthetic Dentistry*, Vol. 87, Issue 4, Page 403-406, April 2002.
- (4) Magne, Douglas, "Additive Contour of Porcelain Veneers; A Key Element in Enamel Preservation, Adhesion and Esthetics for Aging Dentition", *Journal of Adhesive Dentistry*, Vol. 1, Issue 1, page 81-92, 1999.

Trade Show News: Day of Celebration at George Brown

George Brown College and the Faculty of the Dental Technology Program held the Bi Annual Day of Celebration on April 8th from 9:00 am to 5:00 pm. Many companies and organizations were present, such as Burlington Dental Studio who has pledged to give an annual scholarship to the most professional 2nd year student. DENT-LINE OF CANADA INC. donated a Renfert Vario E, a three well dip pot to Ms. Stephanie Dicosmo who was the most improved 2nd year student. Rob Mior was once again the moderator and he introduced many alumni like Jay Mandel RDT, George Paraskevopoulos RDT and Jason Robson RDT. The alumni and program graduates gave a short talk about the path to success that they have travelled followed by a question and answer period. Trevor Langchild RDT provided a seminar to students and guests on his famous porcelain techniques. It was very exciting to see the energy and enthusiasm displayed by all three years of

students. The list of those companies attending represented the major dental manufacturers and suppliers in Canada. Thanks goes out to Bernie Mullen RDT, Carrie, Musa and everyone who helped and donated a gift.



Trade Show News: Dent-Tech West, Edmonton, Alberta

Dent-Tech West took place on Friday April 3rd and Saturday April 4th at the Fantasyland Hotel in the famous Edmonton Mall. Dent-line of Canada Inc., as well as approximately 180 delegates attended. There was a great turn out for Peter T. Pontsa's

seminar "Innovative Attachment Techniques". We would like to thank everyone who attended the seminar and who visited the booth. Special thanks to Ettore Palmeri who organized the speakers and provided cocktails Friday night.

Trade Show News: Upcoming Trade Shows

The Dental Technicians Association of British Columbia are having their 2009 Annual Convention to be held at the Sheraton Vancouver Guilford Hotel in Surrey on September 18th and 19th 2009. This year's theme is Oktoberfest and everyone is encouraged to dress up. There will be a wine and cheese night that provides a relaxing evening to check out the latest products

and meet with other dental technicians and sales representatives. There will also be educational programs on Saturday from 8:30 to 11:30 and 1:30 to 4:30. There will also be a two hour lunch break to allow participants time to visit the exhibitors. Contact the DTA of BC for further information at 1-250-287-6184.